

Autologous Platelet Rich Plasma: Topical Versus Intradermal After Fractional Ablative Carbon Dioxide Laser Treatment of Atrophic Acne Scars

HEBA I. GAWDAT, MD, REHAB A. HEGAZY, MD, MARWA M. FAWZY, MD, AND MARWA FATHY, MD*

BACKGROUND A proposal has recently been made regarding the potential adjuvant use of platelet-rich plasma (PRP) with fractional carbon dioxide laser (FCL) for the correction of acne scars.

OBJECTIVE To compare the efficacy and safety of two administration modes of autologous PRP (intradermal injection (ID) and topical application) after FCL with that of FCL alone in the treatment of atrophic acne scars.

PATIENTS AND METHODS Thirty patients were randomly divided into two groups. Both underwent split-face therapy. Group 1 was administered FCL followed by ID PRP on one side and FCL followed by ID saline on the other. In group 2, one cheek was treated with FCL followed by ID PRP, and the other received FCL followed by topical PRP. Each patient received 3 monthly sessions. The final assessment took place at 6 months.

RESULTS Combined PRP- and FCL-treated areas had a significantly better response ($p = .03$), fewer side effects, and shorter downtime ($p = .02$) than FCL-treated areas, but there were no significant differences in ID- and topical PRP-treated areas in degree of response and downtime ($p = .10$); topically treated areas had significantly lower pain scores.

CONCLUSION The current study introduces the combination of topical PRP and FCL as an effective, safe modality in the treatment of atrophic acne scars with shorter downtime than FCL alone and better tolerability than FCL combined with ID PRP.

The authors have indicated no significant interest with commercial supporters.

Acne scarring causes cosmetic and psychological problems. There has been no standard treatment option for the treatment of acne scars. Various therapeutic options have been described, with variable clinical outcomes and complications, such as surgical techniques (punch graft, punch excision, subcision), resurfacing techniques (dermabrasion, ablative laser treatment, chemical peels), nonablative laser treatment, autologous fat transfer, and injection of dermal fillers.¹

Platelet-rich plasma (PRP) is an autologous concentration of human platelets contained in a small volume of plasma.² Various growth factors,

including platelet-derived growth factor (PDGF), transforming growth factor (TGF), vascular endothelial growth factor, and insulin-like growth factor (IGF), are secreted from the alpha granules of concentrated platelets activated by aggregation inducers.³ These factors are known to regulate processes including cell migration, attachment, proliferation, and differentiation and to promote extracellular matrix accumulation by binding to specific cell surface receptors.^{4,5}

Platelet-rich plasma has recently attracted attention in various medical fields, including plastic surgery and dermatology, for its ability to promote wound

**All the authors are affiliated with the Department of Dermatology, Faculty of Medicine, Cairo University, Cairo, Egypt*

© 2013 by the American Society for Dermatologic Surgery, Inc. • Published by Wiley Periodicals, Inc. • ISSN: 1076-0512 • *Dermatol Surg* 2014;40:152–161 • DOI: 10.1111/dsu.12392

healing.⁶ Studies have documented its effects in ulcer and wound healing,^{7,8} skin rejuvenation,² promoting hair growth,^{9,10} and improvement of striae distensae.^{11,12} Lee and colleagues have proposed its potential as adjuvant therapy in the correction of acne scars.¹³

Fractional ablative carbon dioxide (CO₂) laser (FCL) therapy is based on the theory of fractional photothermolysis. Fractionated ablative laser treatment creates microscopic channels of thermal injury in the skin, causing skin tightening and smoothening through ablation and re-epithelialization and elevation of the floor of depressed scars through collagen remodelling.¹⁴ Despite the documented efficacy of FCL in the treatment of acne scars,^{15–18} its drawbacks, such as long periods of erythema and edema, may cause discomfort¹⁹ and hinder patients' daily lives²⁰, limiting its use. Furthermore, a recent report highlighted the potential risks associated with the use of fractional ablative lasers. The risks fell along a full spectrum of severity that could be long lasting, especially in patients with darker skin phototypes.²¹

The goal was to evaluate combination of PRP and FCL because of the potential synergistic effect and the possible dampening of expected side effects. Therefore, this prospective randomized comparative single-blind clinical trial was conducted to compare the efficacy and safety of combining autologous PRP with FCL in the treatment of atrophic acne scars with that of FCL alone. This study also aimed to compare the efficacy of two modes of administration of autologous PRP (intra-dermal injection and topical application) after FCL in the treatment of atrophic acne scars.

Patients and Methods

The Dermatology Research Ethical Committee, Faculty of Medicine, Cairo University approved this prospective randomized comparative single-blind clinical trial. The study protocol conformed to the ethical guidelines of the 1975 Declaration of

Helsinki. Informed written consents were obtained from all patients before conducting the study.

Thirty patients (18 female, 12 male) aged 19–35 (mean 24.8 ± 4.3) with Fitzpatrick skin phototypes III to V with atrophic acne scars were enrolled in this study. The qualitative scarring grading system that Goodman and Baron²² proposed was used to grade participant acne scars (Table 1). Patients with a history of systemic retinoid therapy within the last 6 months, immunosuppressive drugs, hypertrophic scars or keloid formation, pregnancy, or lactation were excluded.

Patients were randomly assigned to one of two groups. Group 1 (n = 15) underwent split-face therapy with one cheek treated with FCL followed by intra-dermal injection of autologous PRP (area A) and the other cheek treated with FCL followed by intra-dermal injection of normal saline (area B) as a control. Group 2 (n = 15) underwent split-face therapy with one cheek treated with the same regimen as area A (area C) and the other cheek treated with FCL followed by topical application of autologous PRP (area D). Each patient received three treatment sessions at monthly intervals.

Treatment Protocol

Local anesthetic cream (5% lidocaine) was applied to the area to be treated in both groups and under occlusion for 60 minutes before the procedure to minimize pain or discomfort. Then the whole face was cleansed using a mild cleanser and dried with sterile gauze. The cheek was then irradiated with FCL (Smartxide DOT, Advanced CO₂ Fractional technology, DEKA, Florence, Italy). The treatment parameters were power, 15 W; dwell time, 600 μs; spacing, 700 μm; smart stack, level 2. Ice packs were used to minimize heat and pain during and after the procedure. Afterward, the treated areas were randomly assigned to receive intra-dermal injection of autologous PRP (area A) on one side and intra-dermal injection of normal saline (area B) on the other, in group one patients. The treated areas in group

TABLE 1. Qualitative Scar Grading System

<i>Grades of Post Acne Scarring</i>	<i>Level of disease</i>	<i>Clinical features</i>
1	Macular	These scars can be erythematous, hyper- or hypopigmented flat marks. They do not represent a problem of contour like other scar grades but of color
2	Mild	Mild atrophy or hypertrophy scars that may not be obvious at social distances of 50 cm or greater and may be covered adequately by makeup or the normal shadow of shaved beard hair in men or normal body hair if extrafacial
3	Moderate	Moderate atrophic or hypertrophic scarring that is obvious at social distances of 50 cm or greater and is not covered easily by makeup or the normal shadow of shaved beard hair in men or body hair if extrafacial, but is still able to be flattened by manual stretching of the skin (if atrophic)
4	Severe	Severe atrophic or hypertrophic scarring that is evident at social distances greater than 50 cm and is not covered easily by makeup or the normal shadow of shaved beard hair in men or body hair if extrafacial and is not able to be flattened by manual stretching of the skin

two patients were also randomly assigned to receive intradermal injection of autologous PRP (area C) on one side and topical application of 2 mL of autologous PRP (area D) on the other. Injections were administered under sterile conditions, with 0.2 mL of autologous PRP or normal saline injected at 10 different sites approximately 1.5 cm apart. Patients were then instructed to apply pressure using sterile gauze for approximately 15 minutes before leaving.

After each session, all patients were instructed to avoid direct sun exposure, heat, and friction to the treated areas and to apply sunscreen with a sun protection factor of at least 30 daily and antibiotic cream for 1 week after the session.

PRP Preparation

Ten mL of venous blood was drawn from each patient under sterile conditions in a syringe prefilled with 1.5 mL of anticoagulant solution (acid citrate dextrose) and then centrifuged at 150 ×g for 15 minutes. After the first spin, the lower red blood cell portion was discarded, and the supernatant was centrifuged at 400 ×g for 10 minutes. The resulting pellet of platelets was mixed with 1.5 mL of supernatant, which made 1.5 mL of PRP. One mL of 3% calcium chloride was added to the PRP to induce platelet activation.

Patient Assessment

All patients were photographed at baseline and 3 months after the last session (6 months after starting therapy) using a digital camera (Cyber-shot, DSC-HX5V, Sony Corp, Tokyo, Japan). A blinded physician compared photographs using a four-point scale for assessment of clinical improvement of skin smoothness (grade 4, >75% = excellent improvement; grade 3, 51–75% = good improvement; grade 2, 26–50% = fair improvement; grade 1, 0–25% = poor improvement). Clinical satisfaction of the patients was also recorded on a four-point scale²³ 3 months after the last session. Any side effects observed were recorded at each treatment session and during the follow-up period (3 months after the last session). Pain was assessed separately on a scale of 0 (none) to 9 (maximum) at the end of each session, and a mean value for the three sessions of each treated area was calculated.

In addition to digital photography, the depth of acne scars was assessed using a noninvasive imaging technique (optical coherence tomography (OCT); RTVue-100, SD Optovue Inc., Fremont, CA). Cross-line images were made of the treated areas using (CAM-L lens) at baseline and 3 months after the last session (Table 1).

Statistical Methods

Data were statistically described as means and standard deviations, medians and ranges, or number of cases and percentages as appropriate. Comparison of numerical variables between the study groups was done using the Student *t* test for independent samples. Within-group comparison of numerical variables was performed using the paired *t* test for paired (matched) samples. The chi square test was used to compare categorical data. An exact test was used instead when the expected frequency was <5. Within-group data were compared using the McNemar test. $p < .05$ was considered statistically significant. All statistical calculations were performed using SPSS version 15 for Microsoft Windows (SPSS Inc., Chicago, IL).

Results

The current study included 30 patients with atrophic acne scars (12 male, 40.0%; 18 female, 60.0%) aged 19 to 35 (mean 24.8 ± 4.3). The demographic and baseline clinical data of included patients is shown in Table 2.

TABLE 2. Demographic and Baseline Clinical Data of Participants

Characteristic	Group 1	Group 2
Age, mean \pm SD	25.2 \pm 5.0	24.3 \pm 3.7
Sex, n (%)		
Female	10 (66.7)	8 (53.5)
Male	5 (33.3)	7 (46.7)
Fitzpatrick skin phototype, n (%)		
III	7 (46.7)	6 (40.0)
IV	6 (40.0)	7 (46.7)
V	2 (13.3)	2 (13.3)
Acne scar severity, n (%)		
2	3 (20.0)	3 (20.0)
3	8 (53.3)	9 (60.0)
4	4 (26.7)	3 (20.0)
Duration of acne scars, years, mean \pm SD	3.1 \pm 1.1	3.3 \pm 1.0

SD, standard deviation.

Physician and Patient Assessment

According to the physician's assessment, which was done by comparing the clinical photographs of patients at baseline and 3 months after the last session (6 months after starting therapy), the areas treated using the FCL–autologous PRP combination (topical and intradermal) (areas A, C, and D) showed significantly better results ($p = .03$) with regard to clinical improvement of skin smoothness as assessed on the 4-point scale than the area treated using FCL alone (area B). Areas A and C (FCL followed by intradermal PRP) achieved an excellent response (Grade 4, >75% = excellent improvement) in 66.7% of patients (Figure 1), area D (FCL followed by topical PRP) achieved an excellent response in 60% of patients (Figure 2), and area B (FCL alone) achieved an excellent response in 26.7% of patients (Figure 3).

There was no significant difference regarding grade of improvement between areas A and C (intradermal PRP) and area D (topical PRP) ($p = .10$). Patient assessment was similar to that of the physician (Table 3).

Side effects, including erythema, edema, mild crusting, postinflammatory hyperpigmentation (PIH), and acneform eruption, were all of a significantly shorter duration ($p = .02$) in areas treated using the FCL–autologous PRP combination (areas A, C, and D) than in the area treated using FCL alone (area B), leading to significantly shorter total downtime in areas A, C, and D than in area B ($p = .02$) (Table 4).

Pain was present in all areas during the procedure but was significantly greater in areas treated using FCL followed by intradermal injection of PRP (areas A and C) (mean 7.1 ± 1.2) than in the area treated with FCL followed by topical PRP (area D) (mean 2.8 ± 0.6) and the area treated with FCL alone (area B) (mean 3.0 ± 0.7) ($p = .005$).

The OCT images showed significantly greater improvement in measurements of acne scar depth before and after treatment in areas A, C, and D

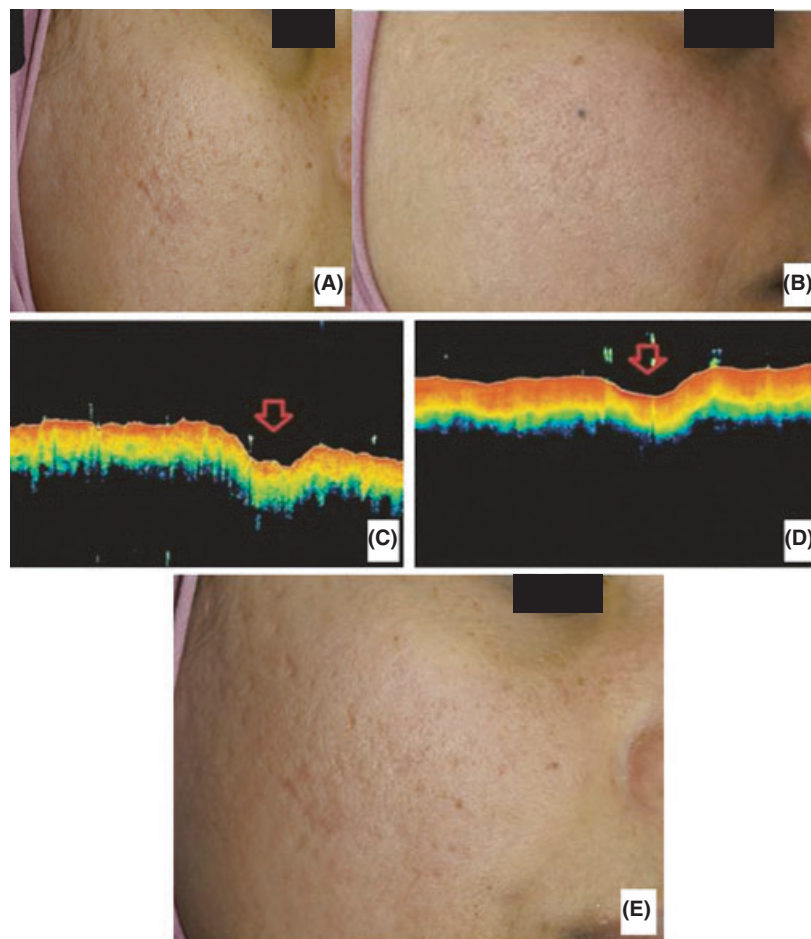


Figure 1. Twenty-seven-year-old woman with moderate (Grade 3) atrophic acne scars (A) at baseline and (B) 3 months after the last treatment session with fractional carbon dioxide laser followed by intradermal injection of autologous platelet-rich plasma. Optical coherence tomography (OCT) cross-line image (scan length 6 mm) of the same area at (C) baseline and (D) 3 months after the last treatment session. Arrow indicates a depression in the surface, which reflects the site of the acne scar shown in the image. (E) Follow-up photograph 6 months after the last treatment session.

(FCL-PRP combination) than in area B (FCL alone) ($p = .01$) (Table 5).

Follow-up

Thirteen patients (seven in group 1, six in group 2) were followed up for three more months after the last treatment session (6 months after the last session). Clinical photographs showed continued improvement in all treated areas. Nevertheless, this was more obvious in areas treated with FCL followed by intradermal injection (Figure 1E) or topical application of autologous PRP (Figure 2E) than in areas treated with FCL alone (Figure 3E).

Discussion

The current study could be added to recent research welcoming the relative new comer PRP to the dermatologic field. It provides further evidence of the potential benefits that the use of PRP offers as an adjuvant to FCL in the treatment of atrophic acne scars. The superiority of the combination was clearly evident in several aspects, including the rapidity and degree of improvement of the acne scars and fewer side effects and shorter downtime. Furthermore, this is the first study to compare two modalities of applying the PRP in the treatment of acne scars, providing an easier mode of application (topical)

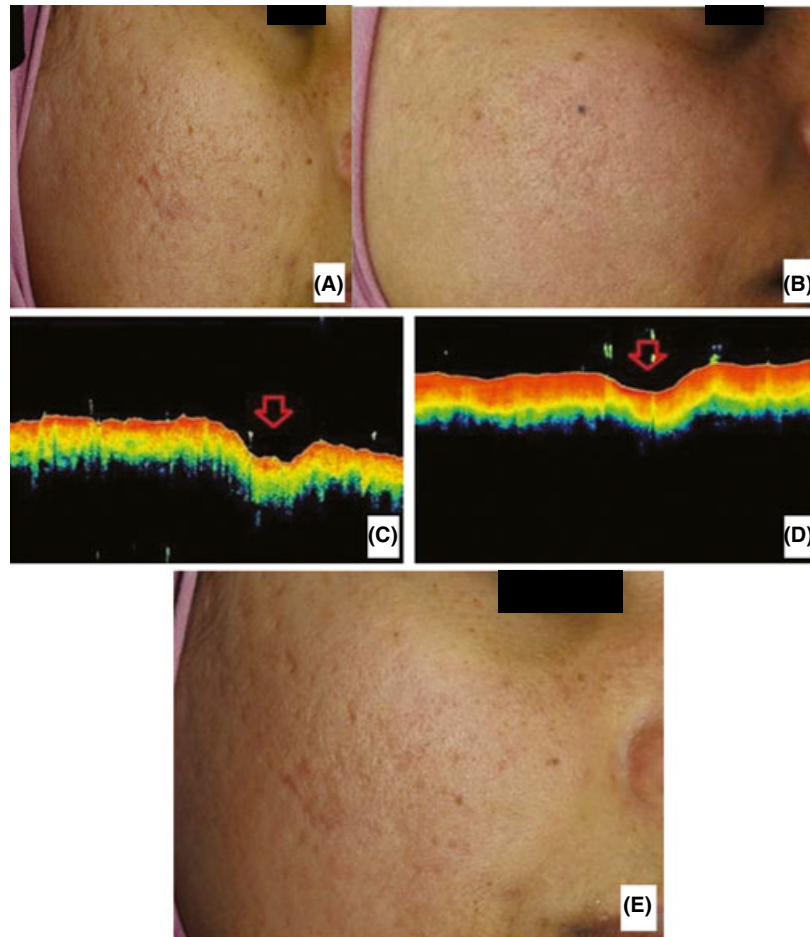


Figure 2. Twenty-seven-year-old woman with moderate (Grade 3) atrophic acne scars (A) at baseline and (B) 3 months after the last treatment session with fractional carbon dioxide laser followed by intradermal injection of autologous platelet-rich plasma. Optical coherence tomography (OCT) cross-line image (scan length 6 mm) of the same area at (C) baseline and (D) 3 months after the last treatment session. Arrow indicates a depression in the surface, which reflects the site of the acne scar shown in the image. (E) Follow-up photograph 6 months after the last treatment session.

with efficacy comparable with that of intradermal injection.

All patients in the current study showed significant improvement regardless of treatment modality, although significantly better results were observed with combined PRP and FCL than with FCL alone, which is in agreement with the results of Lee and colleagues.¹³ This could be attributed to the synergistic effect of both modalities together, naturally giving this combination an advantage. PRP may actively correct atrophic scarring, which is a common sequela from loss of collagen and elastic fibers after inflammatory processes,²² through several mechanisms. The first proposed mechanism would

be the release of growth factors from their alpha-granules, which contain storage pools of numerous growth factors, including PDGF, TGF, vascular endothelial growth factor, insulin-like growth factor, fibroblast growth factor, epithelial growth factor, and keratinocyte growth factor, as well as many cytokines, chemokines, and resulting metabolites.³ Because PRP is by definition platelet rich, it contains correspondingly high levels of these autologous growth factors,²⁴ which could serve in rebuilding the lost collagen and elastic fibers, improving the atrophic scars.

Furthermore, Kakudo and colleagues²⁵ clearly demonstrated how PRP enhanced proliferation of

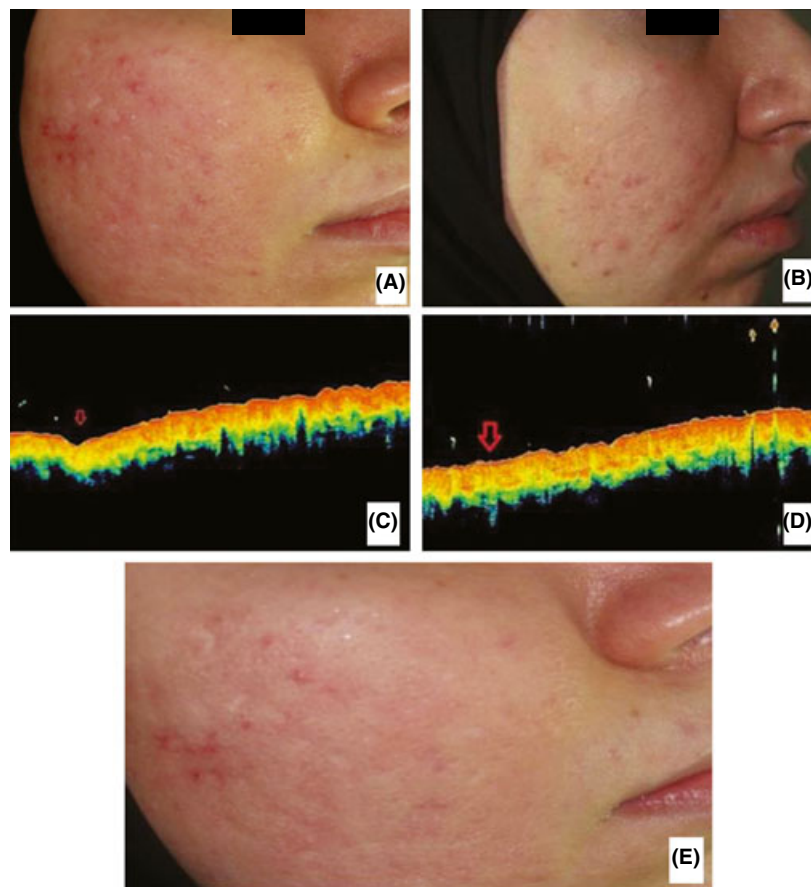


Figure 3. A 20-year-old woman with moderate (Grade 3) atrophic acne scars (A) at baseline and (B) 3 months after the last treatment session with fractional carbon dioxide laser alone. Optical coherence tomography (OCT) cross-line image (scan length 6 mm) of the same area at (C) baseline and (D) 3 months after the last treatment session. Arrow indicates a depression in the surface, which reflects the site of the acne scar shown in the image. (E) Follow-up photograph 6 months after the last treatment session.

TABLE 3. Four-Point Clinical Improvement Scale of Skin Smoothness

Clinical Improvement Grade	Areas A and C		Area B		Area D	
	Physician Assessment	Patient Assessment	Physician Assessment	Patient Assessment	Physician Assessment	Patient Assessment
4: excellent (>75%)	20 (66.7)	16 (53.3)	4 (26.7)	3 (200)	9 (600)	8 (53.3)
3: good (51–75%)	6 (200)	48 (26.7)	6 (40)	5 (33.3)	3 (200)	4 (26.7)
2: fair (26–50%)	4 (13.3)	6 (200)	5 (33.3)	7 (46.7)	3 (200)	3 (200)
1: poor (<25%)	None	None	None	None	None	None

human adipose-derived stem cells, human dermal fibroblasts, and type I collagen, which was attributed to the release of large amounts of PDGF-AB and TGF-β1 by PRP. PDGF is a powerful mitogen for fibroblasts and smooth muscle cells and is

involved in all three phases of wound healing (angiogenesis, the formation of fibrous tissue, and reepithelialization).²⁶ TGF-β is also known to be a weak mitogen for cells derived from the mesoderm, such as fibroblasts,²⁷ and to enhance secretion of

TABLE 4. Side Effects and Total Downtime

Side Effects	Areas A and C	Area B	Area D
Erythema, days, mean \pm SD	2.30 \pm 0.72	3.87 \pm 1.55	2.60 \pm 0.74
Edema, days, mean \pm SD	2.53 \pm 0.63	3.80 \pm 1.00	2.47 \pm 0.52
Mild crusting, days, mean \pm SD	2.31 \pm 0.47	3.46 \pm 1.32	2.33 \pm 0.48
Postinflammatory hyperpigmentation, n (%)	None	2 (13.3)	None
Acneform eruption, days, mean \pm SD	None	None	None
Total downtime, days, mean \pm SD	2.27 \pm 0.69	4.37 \pm 1.52	2.80 \pm 0.56

TABLE 5. Optical Coherence Tomography (OCT) Measurements of Acne Scar Depth at Baseline and After 6 Months

OCT Measurements of Acne Scar Depth	Areas A and C			Area B	Area D
	Mean \pm Standard Deviation (μ m)				
Baseline	92.3 \pm 15.1	92.3 \pm 15.1	92.3 \pm 15.1		
After 6 months	28.9 \pm 8.3	48.8 \pm 16.4	29.8 \pm 8.3		

basement membrane proteins, such as laminin, collagen IV, and tenascin.²⁸ This serves the purpose of rebuilding the lost matrix needed for correction of atrophic scars.

Another pathway that could explain the effect of PRP in the treatment of acne scars could be through the accelerating effect it has on the generation of hyaluronic acid.²⁹ Hyaluronic acid is known to draw water into the hyaluronic acid matrix, causing it to swell, which creates volume and skin turgor and lubricates tissues. There are also indications that native hyaluronic acid promotes cell proliferation and extracellular matrix synthesis and modulates the diameter of the collagen fibers,² improving atrophic scars. The significantly greater improvement in measurements of acne scar depth before and after therapy illustrated in the OCT images of areas A, C, and D (additional PRP) than in area B (FCL) serves as further evidence of the previously suggested beneficial effects of combining PRP with FCL regarding the rebuilding of the lost collagen and elastic tissue,

restoring the skin matrix and correcting the atrophy.

In agreement with others,^{13,30} our work documents that the reported side effects were of significantly shorter duration on the combined treatment sides than on the FCL sides, which led to significantly shorter duration of total downtime on these sides. This could be attributed to all the previously mentioned therapeutic effects of PRP, which would improve the laser-induced wounds. The fact that platelets contain various materials related to angiogenesis and vascular modeling could serve as another explanation. With orchestration of these materials, PRP seems to induce the appropriate level of angiogenesis without causing excessive vessel formation,³¹ ultimately leading to shorter downtime and thereby fewer side effects.

Postinflammatory hyperpigmentation was not reported on any PRP-treated sides, whereas it was reported on two sides (13.3%) receiving FCL alone. Pigmentary incontinence is the most characteristic feature of PIH, which occurs after destruction of the basal cell layer. Melanophages phagocytizing degenerating basal keratinocytes and melanocytes, which contain a large amount of melanin, accumulate in the upper dermis.³² TGF- β in PRP is known to stimulate secretion of basement membrane proteins such as laminin, collagen IV, and tenascin.²⁸ Faster repair of the basement membrane might reduce pigmentary incontinence, resulting in less pigmentation after FCL. Another explanation might be that TGF- β , which PRP releases, is also known to decrease

melanogenesis³³. We believe that this action gives the combined protocol an advantage, which could facilitate optimum results in patients undergoing FCL, especially in those with darker skin phototypes, like in our study.

In the current study, the topically treated PRP sides and the intradermal PRP-treated sides showed comparable improvement in acne scars. We hypothesize that the comparable efficacy might be because the FCL facilitates the penetration of the topically applied PRP through the microscopic channels created, leading to its transepidermal delivery. This drug delivery facilitation by fractional laser has been demonstrated before in other studies.³⁴ The significantly lower pain values that were documented on the topically PRP-treated sides than on the intradermal PRP-treated sides leads us to recommend this protocol over the others because of its greater efficacy and fewer side effects, omitting the need for the painful intradermal injections in an already inflamed face due to the FCL session.

A limitation of the current study might include short follow-up. Furthermore, the evaluation of PRP as a single modality in the treatment of acne scars is worth studying in the future.

In conclusion, the current study introduces the combination of topical PRP and FCL as an effective and safe modality in the treatment of atrophic acne scars with short downtime and good tolerability. The presence of all those advantages in one combination outweighed the other two options in the current study, giving it an advantage over FCL alone or FCL in combination with intradermal PRP in the correction of acne scars.

References

1. Kim HJ, Kim TG, Kwon YS, Park JM, et al. Comparison of a 1,550 nm erbium: glass fractional laser and a chemical reconstruction of skin scars (CROSS) method in the treatment of acne scars: a simultaneous split-face trial. *Lasers Surg Med* 2009;41(8):545–9.
2. Shin MK, Lee JH, Lee SJ, Kim NI. Platelet-rich plasma combined with fractional laser therapy for skin rejuvenation. *Dermatol Surg* 2012;38(4):623–30.
3. Marx RE. Platelet-rich plasma: evidence to support its use. *J Oral Maxillofac Surg* 2004;62(4):489–96.
4. Freymiller EG. Platelet-rich plasma: evidence to support its use. *J Oral Maxillofac Surg* 2004;62(8):1046.
5. Wrotniak M, Bielecki T, Gazdzik TS. Current opinion about using the platelet-rich gel in orthopaedics and trauma surgery. *Ortop Traumatol Rehabil* 2007;9(3):227–38.
6. Kim DH, Je YJ, Kim CD, Lee YH, et al. Can platelet-rich plasma be used for skin rejuvenation? evaluation of effects of platelet-rich plasma on human dermal fibroblast. *Ann Dermatol* 2011;23(4):424–31.
7. Kim SA, Ryu HW, Lee KS, Cho JW. Application of platelet-rich plasma accelerates the wound healing process in acute and chronic ulcers through rapid migration and upregulation of cyclin A and CDK4 in HaCaT cells. *Mol Med Report* 2013;7(2):476–80.
8. Cho JW, Kim SA, Lee KS. Platelet-rich plasma induces increased expression of G1 cell cycle regulators, type I collagen, and matrix metalloproteinase-1 in human skin fibroblasts. *Int J Mol Med* 2012;29(1):32–6.
9. Kang JS, Zheng Z, Choi MJ, Lee SH, et al. The effect of CD34+ cell-containing autologous platelet-rich plasma injection on pattern hair loss: a preliminary study. *J Eur Acad Dermatol Venereol* 2012. doi: 10.1111/jdv.12062. [Epub ahead of print].
10. Li ZJ, Choi HI, Choi DK, Sohn KC, et al. Autologous platelet-rich plasma: a potential therapeutic tool for promoting hair growth. *Dermatol Surg* 2012;38(7 Pt 1):1040–6.
11. Kim IS, Park KY, Kim BJ, Kim MN, et al. Efficacy of intradermal radiofrequency combined with autologous platelet-rich plasma in striae distensae: a pilot study. *Int J Dermatol* 2012;51(10):1253–8.
12. Suh DH, Lee SJ, Lee JH, Kim HJ, et al. Treatment of striae distensae combined enhanced penetration platelet-rich plasma and ultrasound after plasma fractional radiofrequency. *J Cosmet Laser Ther* 2012;14(6):272–6.
13. Lee JW, Kim BJ, Kim MN, Mun SK. The efficacy of autologous platelet rich plasma combined with ablative carbon dioxide fractional resurfacing for acne scars: a simultaneous split-face trial. *Dermatol Surg* 2011;37(7):931–8.
14. Hedelund L, Moreau KE, Beyer DM, Nymann P, et al. Fractional nonablative 1,540-nm laser resurfacing of atrophic acne scars. A randomized controlled trial with blinded response evaluation. *Lasers Med Sci* 2010;25(5):749–54.
15. Asilian A, Salimi E, Faghihi G, Dehghani F, et al. Comparison of Q-Switched 1064-nm Nd:YAG laser and fractional CO₂ laser efficacies on improvement of atrophic facial acne scar. *J Res Med Sci* 2011;16(9):1189–95.
16. Hedelund L, Haak CS, Togsverd-Bo K, Bogh MK, et al. Fractional CO₂ laser resurfacing for atrophic acne scars: a randomized controlled trial with blinded response evaluation. *Lasers Surg Med* 2012;44(6):447–52.
17. Qian H, Lu Z, Ding H, Yan S, et al. Treatment of acne scarring with fractional CO₂ laser. *J Cosmet Laser Ther* 2012;14(4):162–5.

18. Omi T, Kawana S, Sato S, Bonan P, et al. Fractional CO₂ laser for the treatment of acne scars. *J Cosmet Dermatol* 2011; 10(4):294–300.
19. Manuskiatti W, Iamphonrat T, Wanitphakdeedecha R, Eimpunth S. Comparison of fractional erbium-doped yttrium aluminum garnet and carbon dioxide lasers in resurfacing of atrophic acne scars in Asians. *Dermatol Surg* 2013;39(1 Pt 1):111–20.
20. Chapas AM, Brightman L, Sukal S, Hale E, et al. Successful treatment of acneiform scarring with CO₂ ablative fractional resurfacing. *Lasers Surg Med* 2008;40:381–6.
21. Metelitsa AI, Alster TS. Fractionated laser skin resurfacing treatment complications: a review. *Dermatol Surg* 2010;36(3):299–306.
22. Goodman GJ, Baron JA. Postacne scarring: a qualitative global scarring grading system. *Dermatol Surg* 2006;32(12):1458–66.
23. Hu S, Hsiao W-C, Chen M-C, Huang Y-L, et al. Ablative fractional erbium-doped yttrium aluminum garnet laser coagulation mode for the treatment of atrophic acne scars in Asian skin. *Dermatol Surg* 2011;37(7):939–44.
24. Sampson S, Gerhardt M, Mandelbaum B. Platelet rich plasma injection grafts for musculoskeletal injuries: a review. *Curr Rev Musculoskelet Med* 2008;1(3–4):165–74.
25. Kakudo N, Minakata T, Mitsui T, Kushida S, et al. Proliferation-promoting effect of platelet-rich plasma on human adipose-derived stem cells and human dermal fibroblasts. *Plast Reconstr Surg* 2008;122(5):1352–60.
26. Hosgood G. Wound healing: the role of platelet-derived growth factor and transforming growth factor beta. *Vet Surg* 1993; 22(6):490–5.
27. Bennett NT, Schultz GS. Growth factors and wound healing: biochemical properties of growth factors and their receptors. *Am J Surg* 1993;165(6):728–37.
28. Tamariz-Dominguez E, Castro-Munozledo F, Kuri-Harcuch W. Growth factors and extracellular matrix proteins during wound healing promoted with frozen cultured sheets of human epidermal keratinocytes. *Cell Tissue Res* 2002;307(1):79–89.
29. Anitua E, Sanchez M, Nurden AT, Zalduendo MM, et al. Platelet-released growth factors enhance the secretion of hyaluronic acid and induce hepatocyte growth factor production by synovial fibroblasts from arthritic patients. *Rheumatology (Oxford)* 2007;46(12):1769–72.
30. Na JI, Choi JW, Choi HR, Jeong JB, et al. Rapid healing and reduced erythema after ablative fractional carbon dioxide laser resurfacing combined with the application of autologous platelet-rich plasma. *Dermatol Surg* 2011;37(4):463–8.
31. Anitua E, Andia I, Ardanza B, Nurden P, et al. Autologous platelets as a source of proteins for healing and tissue regeneration. *Thromb Haemost* 2004;91(1):4–15.
32. Lacz NL, Vafaie J, Kihiczak NI, Schwartz RA. Postinflammatory hyperpigmentation: a common but troubling condition. *Int J Dermatol* 2004;43(5):362–5.
33. Burd A, Zhu N, Poon VK. A study of Q-switched Nd: YAG laser irradiation and paracrine function in human skin cells. *Photodermatol Photoimmunol Photomed* 2005;21(3):131–7.
34. Issa MC, de Britto Pereira Kassuga LE, Chevrant NS, do Nascimento Barbosa L, et al. Transepidermal retinoic acid delivery using ablative fractional radiofrequency associated with acoustic pressure ultrasound for stretch marks treatment. *Lasers Surg Med* 2012;45(2):81–8.

Address correspondence and reprint requests to: Heba I. Gawdat, MD, 59 Street No. 104, Maadi Gardens, Cairo 11431, Egypt, or e-mail: heba.gawdat@yahoo.com